

## Prometheus bound: Evolution in the management of hepatic trauma—From myth to reality

H. Leon Pachter, MD, *New York, New York*

I want to thank President Britt and the American Association for the Surgery of Trauma (AAST) for bestowing upon me the singular honor of delivering today's Fitts Oration. It is a great honor indeed, and I am humbled by it.

"Mythology comes in two main forms: through folklore or through false premises that have become hallowed through usage."<sup>1</sup> No better example of folklore's influence on hepatic trauma is the myth of Prometheus. Prometheus, for having given fire to mankind, was condemned by the gods to be tied to a stake and have an eagle pluck out a piece of his liver each day. The liver would "regenerate" every night, and thus Prometheus suffered the same fate on a daily basis. It would appear that the ancient Greeks and Romans recognized the liver's ability to "generate" after a portion of it had been traumatically removed. Although there are multiple depictions of aforementioned myth in art, my favorite is by Pieter Paul Rubens (1577–1640) and housed in the Philadelphia Museum of Art. The fierceness depicted by the eagle's talons in Prometheus' forehead and groin, coupled with the bird's beak tearing out a piece of his liver, evokes a feeling of deep empathy for the molecular spontaneity of the protagonist's suffering (Fig. 1).

The second component under the realm of mythology is the concept of false premises that have become "sacred cows" and perpetuate themselves through the concept popularized by Dr. F. A. Simeone<sup>2</sup> known as ideolepsis—a chain idea. Usually, great luminaries expound on their views in the absolute. Often these views become etched in stone, passed on to their students and, in turn, they to their students and so on. No better example of this specious premise, when considering impediments in the management of blunt hepatic injuries, is the statement made in 1977 that "the structure and consistency of liver tissue is unsuitable for spontaneous hemostasis following parenchymal disruption." In essence, the statement was meant to convey that nonoperative management of blunt hepatic injuries is not only impossible but dangerous as well.<sup>3</sup> This concept continued to thrive, and as late as 1990, another surgical luminary opined that "The surgeon must be certain that hollow viscus organs have not been damaged ... In the meantime, it is prudent to operate early to minimize blood loss and avoid missed associated injuries."<sup>4</sup>

The intent of today's oration is to trace the evolution of hepatic trauma, dispel myths, and corroborate realities through evidence-based data.

No talk on the subject of hepatic trauma, at least for me, would be complete without mention of two giants who played a crucial role in my approach to hepatic injuries. The first individual to be mentioned is J. Hogarth Pringle (Fig. 2), who in 1908 described occlusion of the portal triad in arresting hepatic hemorrhage which has since become known as "The Pringle Maneuver."<sup>5</sup> The second individual worthy of mention is Professor Tien Yu Lin, who popularized the "finger fracture technique," an essential maneuver in rapidly exposing intraparenchymal bile ducts and blood vessels.<sup>6</sup>

Pertinent and probing question that currently permeates the surgical atmosphere and the challenge confronting us over the past decade is: as patients with more extensive hepatic injuries are successfully managed nonoperatively, is the operative approach a lost art? In 2000, the *Journal of the American College of Surgeons* under the section "What's

---

From the Department of Surgery, New York University Medical Center, Bellevue Hospital Center, New York, New York.


Presented at the 70th Annual Meeting of the American Association for the Surgery of Trauma, September 16, 2011, Chicago, Illinois.

Address for reprints: H. Leon Pachter, MD, Department of Surgery, New York University Medical Center, Bellevue Hospital Center, 530 First Avenue, Suite 6C, New York, NY 10016.

DOI: 10.1097/TA.0b013e31824b15a7



**Figure 1.** Pieter Paul Rubens: Prometheus Bound (1611–1612). Philadelphia Museum of Art: The W.P. Wiltach Collection.



**Figure 2.** James Hogarth Pringle, 1863–1941.

New in Surgery, Trauma, and Critical Care,” there was no mention of penetrating hepatic trauma nor operative techniques to be used when confronted with the need for urgent surgery in blunt hepatic injuries.<sup>7</sup> Four years later, under the same section in the “What’s New” column, while noting the role of angioembolization, no approaches or techniques were described when the need for operative intervention arose in either penetrating or blunt hepatic injuries.<sup>8</sup> As the number of patients with hepatic injuries requiring surgical intervention, as documented by the National Trauma Data Bank during the years 2000 to 2004 was 14% (n = 1,939)<sup>9</sup>, the question that begs asking is: will current surgical residents be adequately trained to handle these injuries? The data provided by Lucas and Ledgerwood<sup>10</sup> should give us pause for concern. They documented that the average graduating resident, after completing a 5-year clinical program, will have performed an operation to arrest hemorrhage only 1.2 times during their entire residency! My former chairman of surgery, Dr. Frank Cole Spencer, put it best when he said, “When going out bear hunting, you best need to know what to do when meeting up with the bear” (personal communication). With the paradigm shift in trauma/critical care fellowship training to encompass “acute care” surgery, it becomes imperative, in my opinion, that a minimum of 3 months to 4 months should be spent on a hepatobiliary/transplant service rotation. It is only in this manner that adequate exposure to surgery of the liver can be attained so that when the need arises, the trainees will be well prepared.

### BASIC PRINCIPLES IN THE OPERATIVE MANAGEMENT OF COMPLEX HEPATIC TRAUMA

Fortunately, the incidence of complex hepatic injuries has remained steady over the past 25 years at 12% to 15%.<sup>11</sup> The two key initial maneuvers are (i) manual compression of the injury and (ii) resuscitation. It is only at that point that the operating surgeon should make an assessment of the injury. The importance of these two maneuvers cannot be over-emphasized as very few injuries cannot initially be controlled by manual compression, and few, if any, patients can survive without adequate resuscitation. Once the injury has been assessed, the surgical approach I prefer consists of five critical sequential steps:

1. The Pringle Maneuver.
2. Rapid hepatotomy to injury site for ligation of bleeding vessels and lacerated bile ducts.
3. Debridement of nonviable hepatic tissue.
4. Placement of an omental pack into the injury site.
5. Closed suction drainage for grades III-V injuries.

### SAFETY OF PORTAL TRIAL OCCLUSION

Under normothermic conditions, the safe cross-clamping time has been thought to be no more than 15 to 20 consecutive minutes.<sup>12–14</sup> Two methods of extending consec-

utive cross-clamp time are (i) bolus infusion of steroids (20–30 mg/kg of Solumedrol) and (ii) topical hypothermia (cooling the liver to 32°C). The former has been abandoned as experimental data have confirmed that the percentage of ATP (high-energy phosphates) within the liver at 60 minutes is lower than in control animals.<sup>14</sup> Moreover, the incidence of sepsis is increased when steroids are given to injured patients.<sup>15</sup> Topical hypothermia, on the other hand, has been shown to be highly beneficial in preventing ischemia/reperfusion injuries to the liver. Specifically, topical hypothermia has been shown to (i) decrease hepatic PMN infiltration and necrosis; (ii) decrease serum TNF-alpha levels; and (iii) attenuate pulmonary PMN infiltration and microvascular leakage.<sup>14</sup>

### VIALE OMENTAL PEDICLE

The insertion of a viable omental pedicle into an injured liver to arrest hemorrhage was championed by Stone and Lamb.<sup>15</sup> The salient feature which makes the use of this treatment modality attractive lies in the ability of the omentum to (i) effectively exert a hemostatic tamponade effect; (ii) fill “dead space” with vascularized tissue; (iii) introduce peritoneal macrophages, the first line of defense in the peritoneal cavity, into a potential area of sepsis; and (iv) provide stromal call-derived factor 1-alpha, which may be vital to recruiting chemokine receptor cells vital to healing.<sup>16</sup>

### IMPROVISED BALLOON TAMPONADE

High-energy bilobar liver injuries present a unique challenge onto themselves. Hepatotomy via the finger fracture technique for selective ligation of lacerated blood vessels and bile ducts is not applicable to deep bilobar hepatic injuries because the zone of tracheotomy would be far too extensive while simultaneously running the risk of sacrificing multiple uninvolved vessels and bile ducts in both lobes of the liver or in multiple segments. As such, a different approach is required and the improvised balloon technique seems to offer a simple, safe, and effective solution to this problem (Fig. 3)<sup>18</sup>. The balloon when blown up effectively tamponades lacerated vessels. When the balloon is deflated, usually at 24 hours to 36 hours, if no further bleeding ensues it can safely be removed. If, on the other hand, bleeding is evident when the balloon is deflated, reinflation and angio-embolization can be lifesaving.

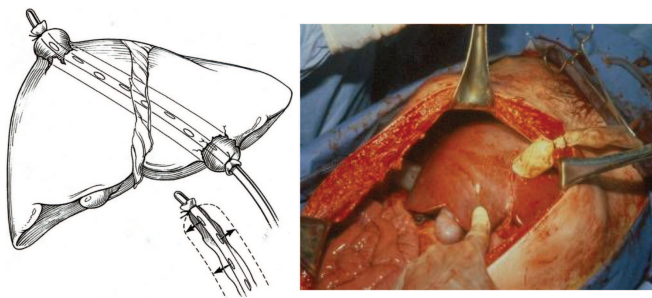


Figure 3. Improvised balloon tamponade.<sup>18</sup>

### HEPATIC RESECTION FOR TRAUMA

Hepatic resection for trauma is infrequently employed, and in the past when resection for hepatic injuries was performed, the ensuing mortality was prohibitive, varying from 52% to 58% (Table 1).<sup>19,20</sup> However, no idea is more appealing than one which appears to offer a solution to a continually vexing problem—how to best deal with complex hepatic injuries? Hepatic resection, as noted, is an old approach but newly appreciated and deserving of serious consideration. What has become patently clear is that poor results in the past could be directly attributed to the “trauma surgeon’s” lack of experience in performing elective major liver resections. Recent reports encompassing nearly 200 hepatic resections for liver injuries performed by hepatobiliary or hepatic transplant surgeons has resulted in a cumulative mortality of only 16% (Table 2).<sup>21–23</sup> These data suggest that hepatic resection for trauma is a viable and safe alternative if an experienced liver surgeon is available to be present in the operating room.

### JUXTAHEPATIC VENOUS INJURY

These injuries are uncommon, but when they do occur, represent the most complex and difficult form of hepatic trauma. As most trauma surgeons are unfamiliar with the nuances of the anatomy of the retrohepatic cava and hepatic veins, coupled with the complexity of the injury, mortalities ranging between 50% and 80% are often cited. When the mechanism of injury is a result of blunt trauma, few, if any, survivors are reported. In trying to analyze why mortality rates with this injury are so high, a review of decades-long approaches to juxtahepatic venous injuries is in order. The overall strategy has revolved around two basic concepts: (i) wide hepatic mobilization and (ii) direct venous repair of the injury. The methods by which direct venous repair have been attempted are listed below:

1. Atrial-caval shunting.
2. Veno-venous bypass.
3. Sequential vascular clamping.
4. Finger fracture to the injury for direct repair with no attempts at vascular isolation.
5. Deep omental packing.

TABLE 1. Hepatic Resection for Trauma

Author	Patients	Incidence	Mortality
Pachter et al. <sup>19</sup>	5,000	7.5%	52%
Cogbill et al. <sup>20</sup>	1,335	0.9%	58%

TABLE 2. Hepatic Resection for Trauma

Author	Patients	Blunt (%)	Mortality (%)
Strong et al. <sup>21</sup>	37	90	81
Tsugawa et al. <sup>22</sup>	100	100	24
Polanco et al. <sup>23</sup>	56	75	18*

\* 9% hepatic related.

A critical review of the management strategies when confronting a juxtahepatic venous injury by Buckman et al.<sup>23</sup> has identified a serious flaw in the previous conception that wide hepatic mobilization is an essential maneuver. On the contrary, injudicious disruption of the natural containing structures such as the suspensory ligaments that surround the hepatic venous segments may lead to rapid exsanguinating hemorrhage which inevitably proves to be fatal. The better part of valor would be to dispense with the concept of “wide hepatic mobilization” and embark on other treatment strategies designed to arrest bleeding.

### ATRIOCAVAL SHUNTING

J. D. Richardson<sup>25</sup> in his Scudder Oration at the 90th American College of Surgeons Clinical Congress cited 412 shunt insertions culled from the literature up to 2004, with an ensuing mortality of 88%. Based on the scarcity of its use and the prohibitive mortality associated with atriocaval shunt insertion, it would appear that shunt insertion has been relegated to the “recycling bin” of surgically discarded procedures.

### EXTRACORPOREAL SHUNTING

Fewer than 10 patients with juxtahepatic venous injuries who survived after undergoing veno-veno bypass have been described.<sup>26,27</sup> Biffi and Moore emphasize the splanchnic decompression via the inferior mesenteric vein lest significant fluid sequestration and bowel edema ensue (Fig. 4). Although this approach can be lifesaving, lack of familiarity with its use and need for the presence of a “pump” technician severely limits its use.

### VASCULAR ISOLATION TECHNIQUES

This technique involves cross-clamping the portal triad, the infrarenal cava, the intrapericardial cava, and the aorta at the diaphragmatic hiatus. Yellin et al. describes six cases where this technique was used. A closer inspection of the article reveals that in four of the cases, an intracaval shunt was used with two patients surviving, and in only two instances was the sequential clamping technique used with one survivor.<sup>28</sup> The latter method is fraught with significant pitfalls as hypovolemia, which already is present, is merely

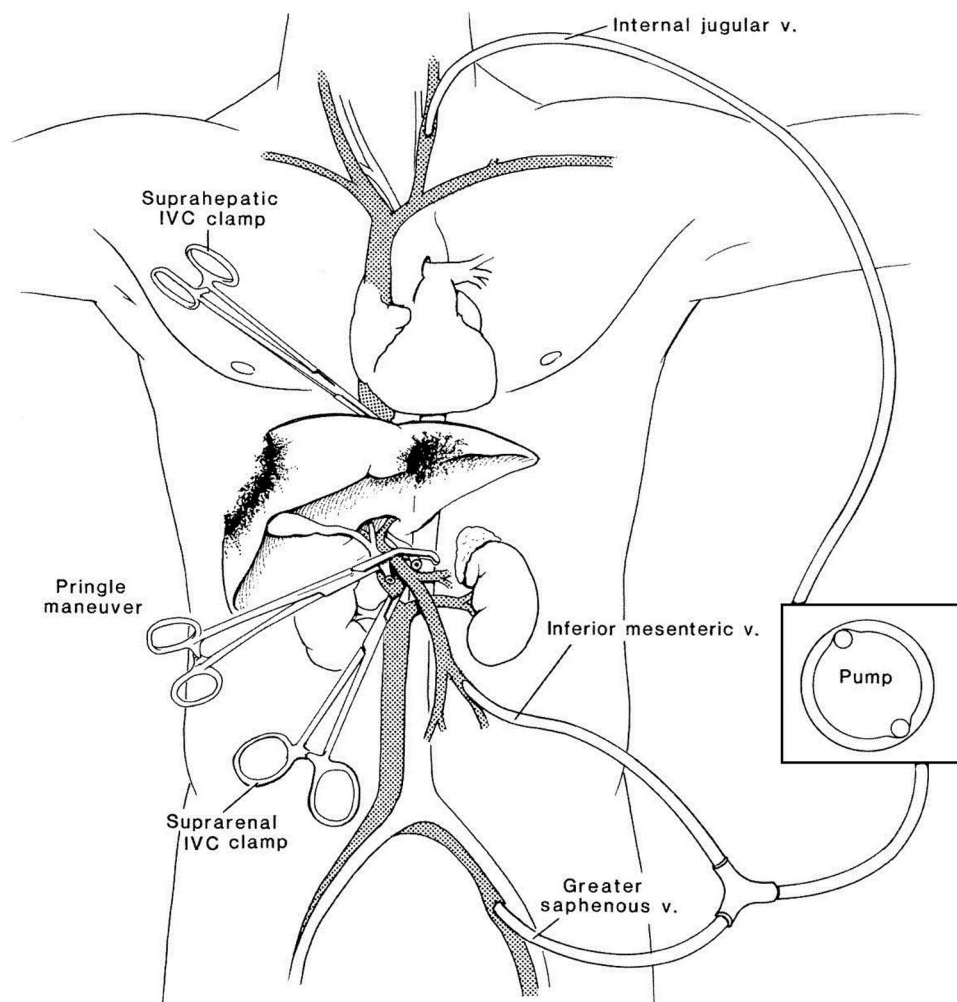


Figure 4. Extracorporeal shunting.<sup>27</sup>

compounded by a lack of adequate preload as a result of the total vascular occlusion. In addition, when attempting such a procedure, the heart is prone to arrhythmias which often prove to be fatal.

In the new millennium, it has been widely accepted that complex hepatic injuries including those to the juxtahepatic venous structures are best managed by a multidisciplinary approach. Asensio et al.<sup>29</sup> were the first to detail this type of treatment strategy. Using a combination of a direct approach to the injury, “damage control” with perihepatic packing and angioembolization, Asensio et al. were able to achieve a 63% (32 of 51) survival for grade IV injuries and a 23% (12 of 52) survival in Grade V injuries. Refining the multidisciplinary approach to complex hepatic injuries, both Denton et al.<sup>30</sup> and Beitner et al.<sup>31</sup> demonstrated the efficacy of the insertion of covered endostents in the management of injuries to the juxtahepatic venous structures.

### PERHEPATIC PACKING AND JUXTA-HEPATIC VENOUS INJURIES

In 1990, Cue et al.<sup>32</sup> and Beal<sup>33</sup> both independently reported the survival of four patients each when perihepatic packing was the main method of treating a juxtahepatic venous injury. The article by Beal<sup>33</sup> is quite enlightening in that she describes gaining control of hemorrhage from a juxtahepatic venous injury by packing while she fashioned an atriocaval shunt. In an attempt to insert the shunt, the patient exsanguinated thus giving rise to the idea that if packing controlled the injury, no further attempts at surgical intervention are justified. Instead, a damage control laparotomy is completed, and the patient is returned to the operating room after adequate resuscitation usually 42 hours to 72 hours after the initial injury.

The efficacy of this philosophy was further corroborated by Liu, who compared two groups of patients with blunt juxtahepatic venous injuries. Group I consisted of 10 patients who were initially packed and then underwent additional adjunctive techniques, versus 9 patients where direct repair of the injury was attempted. Mortality for the direct approach was 75% compared with only 45% for the group managed by “packing” and a multidisciplinary approach.<sup>34</sup>

### HEPATIC TRANSPLANTATION AND HEPATIC TRAUMA

At present, there are only 20 reported cases of hepatic transplantation for severe liver injuries. Indications for hepatic transplantation in the setting of extremely complicated injuries are as follows: (i) uncontrollable hemorrhage despite all methods of intervention; (ii) postoperative hepatic failure either acute or progressive; and (iii) injuries to the main portal triad structure that cannot be reconstructed.<sup>35–37</sup> Clearly, the most limiting factor in the employment of this technique is the lack of available organs for transplantation. Usually, a two-stage approach is adopted. The first stage consists of removing the injured liver and creating a temporary porta caval shunt. The second stage, the actual liver replacement,

takes place after an organ has been procured, which at times may take up to 2 days.

### DAMAGE CONTROL

The guiding principle that should initiate immediate implementation of “damage control,” which has stood the test of time, was best summed up by Burch et al. in 1992: “The critical and most crucial step is the recognition of the patient’s imminent death and instituting measures to terminate the procedure.”<sup>38</sup> The warning signs are always there and usually manifest themselves by the presence of the “triad of death”: hypothermia, acidosis, and coagulopathy. If, however, at this juncture in time, “damage control” maneuvers are employed only as a “last desperate maneuver,” death will ensue nevertheless. When damage control is used as an “adjunctive maneuver” in severe complex hepatic trauma, up to 67% of patients will survive, versus only 2% when used as a “last desperate maneuver” (Table 3).<sup>39</sup>

Complication-associated with damage control laparotomy and intra-abdominal packing is the development of abdominal compartment syndrome. The reported incidence of this complications remains at 28%, but the figure is probably lower with the current use of abdominal vac dressings.<sup>40</sup> Decompressive laparotomy is warranted when intra-abdominal pressures, measured by a Foley catheter, exceed 25 mm Hg to 29 mm Hg. More recently, Cheatam and Ivatury noted that the critical intra-abdominal pressure that causes end organ dysfunction varies from patient to patient as a result of differences in comorbidities and physiology. They believe that the abdominal perfusion pressure (APP) is a more accurate reflection of intra-abdominal hypertension than the measurement of intra-abdominal pressure. The APP can be calculated as follows:

$$APP = \text{mean arterial pressure (MAP)} - IAP$$

When the APP is less than 60 mm Hg, decompressive laparotomy is indicated.<sup>41</sup> Methods of dealing with the presence of abdominal compartment syndrome are (i) Bogota bag; (ii) VAC abdominal dressing; (iii) absorbable mesh; and (iv) abdominal component separation. Presently, the use of an abdominal VAC dressing has been noted to be used most often, in part because of its ease of availability and deployment.

### TIMING OF PACKING REMOVAL

The timing of packing removal can only be considered after the physiologic status of the patient has been restored,

TABLE 3. Perihepatic Packing

Author	Last Desperate Maneuver		Adjunctive Maneuver	
	Number of Patients	Survivors	Number of Patients	Survivors
Feliciano <sup>39</sup>	17	0	49	28 (57%)
Cogbill et al. <sup>20</sup>	18	1	34	20 (59%)
Cue et al. <sup>32</sup>	12	0	23	23 (100%)
Total	47	1 (2%)	106	71 (67%)

**TABLE 4.** Timing of Packing Removal

Author	N	Removal (hr)	Abscess Rate
Abikhaleh et al. <sup>42</sup>	35	<72	Not increased
Caruso et al. <sup>43</sup>	129	36–72	Not increased
Nicol et al. <sup>44</sup>	93	48	Not increased

which, at minimum, takes 36 hours. What has become evident is that the premature removal of packing (<24 hours) runs the significant risk of hemorrhage, while packing removal >72 hours increases the risk of sepsis. The optimal time of packing removal is currently unknown but should be at least 48 hours after the injury (Table 4).<sup>42–44</sup>

### NONOPERATIVE MANAGEMENT OF PENETRATING HEPATIC TRAUMA

Renz and Feliciano reported on seven cases of penetrating hepatic trauma to the right thoraco-abdominal region where the patients were stable and followed successfully with CT imaging.<sup>45</sup> The safety of this approach has been corroborated by both Navsaria<sup>46</sup> and Fikry<sup>47</sup>, who report success rates of 92% and 82% respectively. The data from the National Pediatric Trauma registry, however, should give us some pause when considering this approach. Of the 1,147 hepatic injuries reported, 132 (12%) were penetrating and, of these, 55 (n=6) were managed nonoperatively. The eye-opening and frightening data, however, stem from the fact that of the remaining 126 patients who underwent surgical intervention, 84% had associated injuries of which 50% were hollow viscus.<sup>48</sup>

### NONOPERATIVE MANAGEMENT OF BLUNT HEPATIC TRAUMA

In an editorial comment on the merits of nonoperative management of blunt hepatic trauma, the late Dr. Alex Walt noted, "It is important to reiterate that any nonsurgical approach adds greatly to the responsibility of the surgeon. The surgeon is much more likely to be chastised for any untoward outcome than applauded for commendable restraint."<sup>49</sup> How prophetic!

The inclusion criteria for nonoperative management of blunt hepatic trauma are all well-known to this audience, but by way of review they are (i) hemodynamic stability (most important); (ii) computed tomography (CT) scan delineation of the injury; (iii) absence of associated injuries on CT scan requiring operative intervention; and (iv) limited need for hepatic-related blood transfusions.

Major concern regarding the nonoperative management of blunt hepatic trauma was the spectre of missing a hollow viscus injury. This concern has been much exaggerated as the incidence of hollow viscus injury in the presence of isolated hepatic trauma is only 1%.<sup>25</sup> Tip-off signs found on CT imaging studies pointing to the possibility of a hollow viscus injury are (i) presence of fluid in the peritoneal cavity or pelvis with Hounsfield units <10; (ii) free peritoneal or retroperitoneal air; (iii) focal areas of

**TABLE 5.** Complications: Nonoperative Management of Blunt Hepatic Trauma

Author	N (%)	Op (n)	Grade IV (%)
Pachter et al. <sup>50</sup>	404 (5)	6	66
Goldman et al. <sup>51</sup>	153 (12)	15	27
Kozar et al. <sup>52</sup>	453 (13)	28	52

bowel thickening or bowel wall enhancement; and (iv) isolated intraperitoneal fluid collections.

The success rate of nonoperative management of blunt hepatic injuries, for patients meeting inclusion criteria, has uniformly been reported to be in the range of 80% to 90%.<sup>25</sup> Complications resulting from nonoperative management, not unexpectedly, rise in tandem with grade of injury. Overall, in a cumulative review of 1,010 cases culled from three major studies, the incidence of complications is 10% with only 5% (n = 49) requiring operative intervention (Table 5).<sup>50–52</sup> When nonoperative management fails or when operative management of blunt hepatic injuries is indicated from the very onset, a useful algorithmic approach with an annotated discussion of each step is delineated in the Western Trauma Association/Critical Decisions in Trauma (Fig. 5).<sup>53</sup>

### POSTOPERATIVE IMAGING

Postoperative imaging rarely ever influences patient management and should only be dictated by the patient's clinical course.<sup>54,55</sup>

### TIMING OF RETURN TO NORMAL ACTIVITIES

The usual 6 months, a common time period suggested to refrain from vigorous activities, is not supported by scientific data. On the contrary, experimental work by Dulchavsky et al.<sup>56</sup> suggest that the wound-breaking strength of the healing liver at 6 weeks to 8 weeks is equal to or exceeds that of the normal liver. Having said that, and based on personal experience, I would still advocate a repeat scan at 3 months for any patient having greater than a grade III injury before allowing that patient to return to contact sports.

### PREDICTORS OF FAILURE IN NONOPERATIVE MANAGEMENT

Several factors have been delineated as having a high correlation rate with failure of nonoperative management of blunt hepatic injuries:

1. Rising intra-abdominal pressure: Chen et al.,<sup>57</sup> in a study of 25 patients, showed a strong correlation between a rise in intra-abdominal pressure (>25 cm H<sub>2</sub>O) and failure of nonoperative management.
2. Grade of injury: It stands to reason that as the grade of injury increases, the likelihood of eligibility for nonoperative management decreases. In a multicenter study encompassing 404 patients, Pachter et al.<sup>50</sup> noted that only 14% of grades IV–V injuries qualified

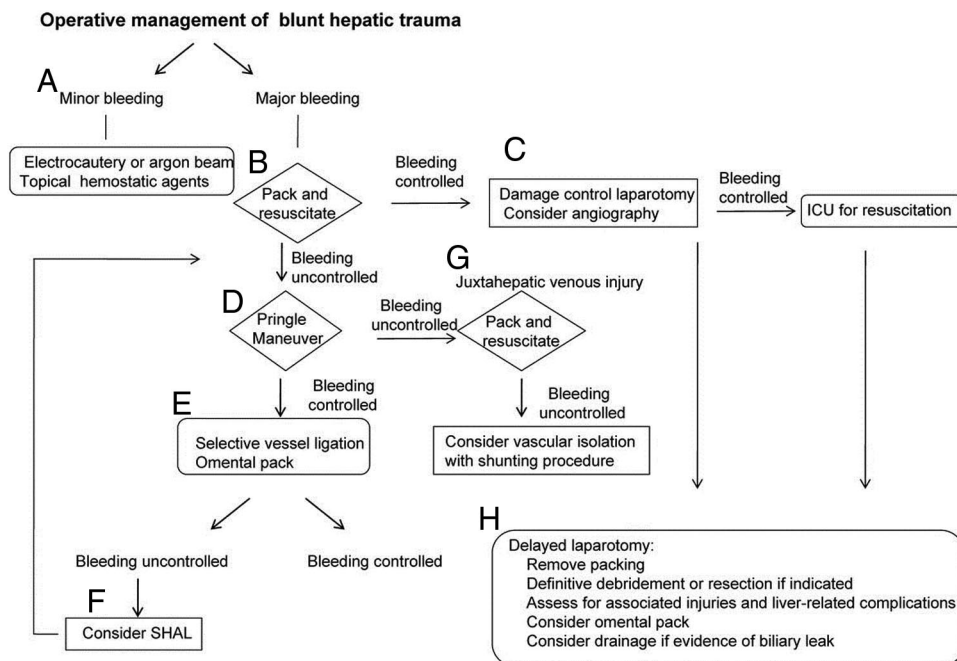


Figure 5. Operative management of adult blunt hepatic trauma.<sup>53</sup>

for nonoperative intervention. More importantly, 66% of the failures of nonoperative management were classified as being grade IV-V injury. Carrillo et al.,<sup>58</sup> on the other hand, noted that 66% of grades IV-V injuries could be managed nonoperatively, but 50% of these required some type of interventional treatment, most notably angioembolization.

3. Hemoperitoneum: Some maintain that the degree of hemoperitoneum is irrelevant as long as hemodynamic stability is maintained. While this may be true, I believe a reasonable and prudent approach would be to observe the patient if the hemoperitoneum is <500 mL or to resort to angiography if >500 mL is noted.
4. Pooling of contrast material: Pooling of contrast material is not “one size fits all.” On imaging studies, there are three types of classifications of pooling of contrast material<sup>59</sup>:
  - a. Type I: Extravasation and pooling of contrast material into the peritoneal cavity.
  - b. Type II: Simultaneous pooling of contrast material within the hepatic parenchyma.
  - c. Type III: Pooling of contrast material within the hepatic parenchyma.

Type I almost always requires operative intervention, whereas Types II and III are usually amenable to angioembolization.

### ANGIOEMBOLIZATION

The primary role of angioembolization is in the nonoperative management of blunt hepatic trauma. Angioembo-

lization also plays an adjunctive role in both the management of intraoperative and postoperative hepatic bleeding.

### CONCLUSION

In her recent book, *The Watchman's Rattle*, after an exhaustive analysis of ancient Mayan and Egyptian civilizations, Rebecca Costa<sup>60</sup> came up with a theory as to why these great civilizations rapidly spiraled into oblivion. Her hypothesis was that these civilizations reached a “cognitive threshold” and were unable to resolve complex problems. Instead of adapting to change, they fell back on survival techniques that worked in the past without recognition that those techniques had little relevance in an ever-changing world. As a result, they resorted to irrational behavior which eventually led to their demise.

The challenge before us today is never to reach that “cognitive threshold” but instead seek innovative and adaptive ways to make that progressive and necessary quantum leap forward. For it is only in this manner that we can prevent losing relevance and fading into oblivion.

### DISCLOSURE

The author declares no conflicts of interest.

### REFERENCES

1. Walt AJ. The mythology of hepatic trauma or Babel revisited. *Am J Surg.* 1978;135:12–18.
2. Simeone FA. Shock, trauma and the surgeon. *Ann Surg.* 1962;158:759–754.
3. Flint LM, Mays ET, Aaron WS, Fulton RL, Polk HC. Selectivity in the management of hepatic trauma. *Ann Surg.* 1977;185:613–618.
4. Trunkey DD. Invited commentary in Federico JA, Horner WR, Clark DE, et al. Blunt hepatic trauma: nonoperative management in adults. *Arch Surg.* 1990;125:905–909.

5. Pringle JH. Notes on the arrest of hemorrhage due to trauma. *Ann Surg.* 1908;48:546–566.
6. Lin TY, Lee CS, Chen KM, Chen CC. Role of surgery in the treatment of primary carcinoma of the liver: a 31 year experience. *Br J Surg.* 1987;74:839–842.
7. McCarthy MC. What's new in surgery trauma and critical care. *J Am Coll Surg.* 2000;190:232–243.
8. Rozycki G. What's new in surgery trauma and critical care. *J Am Coll Surg.* 2004;198:798–805.
9. Tinkoff G, Esposito TJ, Reed J, et al. American Association for Surgery of Trauma Organ Injury Scale I: spleen, liver, and kidney, validation based on the National Trauma Data Bank. *J Am Coll Surg.* 2008;207:646–655.
10. Lucas CE, Ledgerwood AM. The academic challenge of teaching psychomotor skills for hemostasis of solid organ injury. *J Trauma.* 2009;66:636–640.
11. Richardson JD, Franklin GA, Lukan JK, et al. Evolution in the management of hepatic trauma: a 25 year perspective. *Ann Surg.* 2000;232:324–330.
12. Pachter HL, Spencer FC, Hofstetter SR, Liang HG, Coppa GF. Significant trends in the treatment of hepatic trauma. Experience with 411 injuries. *Ann Surg.* 1992;215:492–500.
13. Pachter HL, Spencer FC, Hofstetter SR, Liang HC, Coppa GF. The management of juxtahepatic venous injuries without an atriocaval shunt: preliminary clinical observations. *Surgery.* 1986;99:569–575.
14. Patel S, Pachter HL, Yee H, Schwartz JD. Topical hypothermia attenuates pulmonary injury after hepatic ischemia reperfusion. *J Am Coll Surg.* 2000;191:650–656.
15. Demaria EJ, Reichman W, Kenney PR, Armitage JM, Gann DS. Septic complications of corticosteroid administration after central nervous system trauma. *Ann Surg.* 1985;202:248–52.
16. Stone HH, Lamb JM. Use of pedicled omentum as an autologous pack for control of hemorrhage in major injuries of the liver. *Surg Gynecol Obstet.* 1975;141:92–94.
17. Naveed US, McGuire PG, Howdieshell TR. The omentum is a site of stromal cell-derived factor 1alpha production and reservoir for CXCL12 chemokine receptor 4-positive cell recruitment. *Am J Surg.* 2010;200:276–282.
18. Poggetti RS, Moore EE, Moore FA, Mitchell MB. Balloon tamponade for bilobar transfixing hepatic gunshot wounds. *J Trauma.* 1992;33:694–697.
19. Pachter HL, Spencer FC, Hofstetter SR, Coppa GF. Experience with the finger fracture technique to achieve intra-hepatic hemostasis in 75 patients with severe injuries to the liver. *Ann Surg.* 1983;197:771–778.
20. Cogbill TH, Moore EE, Jurkovich GJ. Severe hepatic trauma: a multi-institutional experience with liver injuries. *J Trauma.* 1988;28:1433–1438.
21. Strong RW, Lynch SV, Wall DR. Anatomic resection for severe liver trauma. *Surgery.* 1998;125:251–257.
22. Tsugawa K, Koyanagi N, Hashizume M, et al. Anatomic resection for severe blunt liver trauma in 100 patients: significant differences between young and old. *World J Surg.* 2002;26:544–549.
23. Polanco P, Leon S, Pineda J, et al. Hepatic resection in the management of complex injury to the liver. *J Trauma.* 2008;65:1264–1270.
24. Buckman RF, Miraliakbari R, Badellino MM. Juxtahepatic venous injuries: a critical review of reported management strategies. *J Trauma.* 2000;48:978–984.
25. Richardson JD. Changes in the management of injuries to the liver and spleen. *J Am Coll Surg.* 2005;200:648–668.
26. Rodgers FB, Reese J, Shackford SR, Osler TM. The use of venovenous bypass and total vascular isolation of the liver in the surgical management of juxtahepatic venous injuries in blunt hepatic trauma. *J Trauma.* 1997;43:530–533.
27. Biffi WL, Moore EE, Franciose RJ. Venovenous bypass and hepatic vascular isolation as adjuncts in the repair of destructive wounds of the retrohepatic inferior vena cava. *J Trauma.* 1998;45:400–403.
28. Yellin AE, Chaffee CB, Donovan AJ. Vascular isolation in the treatment of juxtahepatic venous injuries. *Arch Surg.* 1971;102:566–573.
29. Asensio JA, Roldan G, Petrone P, et al. Operative management and outcomes in 103 AAST-OIS grades IV-V complex hepatic injuries: trauma surgeons still need to operate, but angioembolization helps. *J Trauma.* 2003;54:647–654.
30. Denton JR, Moore EE, Caldwell DM. Multimodality treatment for grade V hepatic injuries: perihaptic packing, arterial embolization, and venous stenting. *J Trauma.* 1997;42:964–968.
31. Beitner MM, Suh N, Dowling R, Miller JA. Penetrating liver injury managed with a combination of balloon tamponade and venous stenting. A case report and literature review. *Injury.* 2011;43:119–122.
32. Cue JI, Cryer HG, Miller FB, Richardson JD, Polk HC Jr. Packing and planned re-exploration for hepatic and retroperitoneal hemorrhage critical refinements of useful techniques. *J Trauma.* 1990;30:1007–1014.
33. Beal SL. Fatal hepatic hemorrhage: an unresolved problem of complex liver injuries. *J Trauma.* 1990;30:163–169.
34. Liu PP, Chen CL, Cheng YF, et al. Use of refined operative strategy in combination with a multidisciplinary approach to manage blunt juxtahepatic venous injuries. *J Trauma.* 2005;59:940–945.
35. Ringe B, Pichlmayr R. Total hepatectomy and liver transplantation: a life saving procedure in patients with severe hepatic trauma. *Br J Surg.* 1995;82:837–839.
36. Esquivel CO, Bernardos A, Makowka L, Iwatsuki S, Gordon RD, Starzl TE. Liver replacement after massive hepatic trauma. *J Trauma.* 1987;27:800–802.
37. Delis SG, Bakoyiannis A, Selvaggi G, Weppeler D, Levi D, Tzakis AG. Liver transplantation for severe hepatic trauma: experience from a single center. *World J Gastroenterol.* 2009;15:1641–1644.
38. Burch JM, Ortiz VB, Richardson RJ, Martin RR, Mattox KL, Jordan GL Jr. Abbreviated laparotomy and planned reoperation for critically injured patients. *Ann Surg.* 1992;21:476–483.
39. Feliciano DV, Mattox KL, Burch JM, Bitondo CG, Jordan GL Jr. Packing for control of hepatic hemorrhage. *J Trauma.* 1986;26(8):738–43.
40. Morris JA Jr, Eddy VA, Blinman TA, Rutherford EJ, Sharp KW. The staged celiotomy for trauma. Issues in unpacking and reconstruction. *Ann Surg.* 1993;217:576–584.
41. Cheatam ML, Malbrain ML, Kirkpatrick A, et al. Results from the International conference of Experts on Intra-abdominal Hypertension and Abdominal Compartment Syndrome. II Recommendations. *Intensive Care Med.* 2007;33:951–962.
42. Abikhaled JA, Granchi TS, Wall MJ, Hirshberg A, Mattox KL. Prolonged abdominal packing for trauma is associated with increased morbidity and mortality. *Am Surg.* 1997;63:1109–1112.
43. Caruso DM, Battistella FD, Owings JT, Lee SL, Samaco RC. Perihaptic packing of major liver injuries: complications and mortality. *Arch Surg.* 1999;134:958–962.
44. Nicol AJ, Hommes M, Primrose R, Navsaria PH, Krige JE. Packing for control of hemorrhage in major liver trauma. *World J Surg.* 2007;31:569–574.
45. Renz BM, Feliciano DV. Gunshot wounds to the right thoracoabdomen: a prospective study of nonoperative management. *J Trauma.* 1994;37:737–744.
46. Navsaria PH, Nicol AJ, Krige JE, Edu S. Selective management of liver gunshot injuries. *Ann Surg.* 2009;249:653–656.
47. Fikry K, Velmahos GC, Bramos A, et al. Successful selective management of abdominal gunshot wounds despite low penetrating trauma volumes. *Arch Surg.* 2011;146:528–532.
48. Dicker RA, Sartorelli KH, McBriers WJ, Vane DW. Penetrating hepatic trauma in children: operating room or not. *J Pediatr Surgery.* 1996;31:1189–1191.
49. Walt A. Invited Commentary in Hiatt JR, Harrier DH, Koenig BV. Management of major blunt liver injury with hemoperitoneum. *Arch Surg.* 1990;125:101–103.
50. Pachter HL, Knudson MM, Esrig B, et al. Status of nonoperative management of blunt hepatic injuries in 1995: a multicenter experience with 404 patients. *J Trauma.* 1996;40:31–38.
51. Goldman R, Zilkoski M, Mullins R, Mayberry J, Deveney C, Trunkey D. Delayed celiotomy for the treatment of bile leak, compartment syndrome, and other hazards of nonoperative management of blunt liver injury. *Am J Surg.* 2003;185:492–497.
52. Kozar RA, Moore FA, Cothren CC, et al. Risk factors for hepatic morbidity following nonoperative management: multicenter study. *Arch Surg.* 2006;141:451–458.

53. Kozar RA, Feliciano DV, Moore EE, et al. Western Trauma Association/critical decisions in trauma: operative management of adult blunt hepatic trauma. *J Trauma*. 2011;71:1–5.
54. Davis KA, Brody JM, Cioffi WG. Computed tomography in blunt hepatic trauma. *Arch Surg*. 1996;131:255–260.
55. McMahon DJ, Grossman MD, Schiller HJ, et al. Nonoperatively managed hepatic injuries. *J Trauma*. 1996;41:370–371.
56. Dulchavsky SA, Lucas CE, Ledgerwood AM, Grabow D, An T. Efficacy of liver wound healing by secondary intent. *J Trauma*. 1990;30:44–48.
57. Chen RJ, Fang JF, Chen MF. Intra-abdominal pressure monitoring as a guideline in the non operative management of blunt hepatic trauma. *J Trauma*. 2001;51:44–50.
58. Carrillo EH, Wohltmann C, Richardson JD, Polk HC Jr. Evolution in the treatment of complex blunt liver injuries. *Curr Prob Surg*. 2001;38: 1–60.
59. Fang JF, Chen RJ, Wong YC, et al. Classification and treatment of pooling of contrast material on computer tomographic scan of blunt hepatic trauma. *J Trauma*. 2000;49:1083–1088.
60. Costa RD. *The Watchman's Rattle: Thinking Our Way Out of Extinction*. Philadelphia, PA: Vanguard Press; 2010.